

# Management of Bartholin's Duct Cyst and Gland Abscess

FOLASHADE OMOLE, M.D., BARBARA J. SIMMONS, M.D., and YOLANDA HACKER, M.D.  
Morehouse School of Medicine, Atlanta, Georgia

Bartholin's duct cysts and gland abscesses are common problems in women of reproductive age. Bartholin's glands are located bilaterally at the posterior introitus and drain through ducts that empty into the vestibule at approximately the 4 o'clock and 8 o'clock positions. These normally pea-sized glands are palpable only if the duct becomes cystic or a gland abscess develops. The differential diagnosis includes cystic and solid lesions of the vulva, such as epidermal inclusion cyst, Skene's duct cyst, hidradenoma papilliferum, and lipoma. The goal of management is to preserve the gland and its function if possible. Office-based procedures include insertion of a Word catheter for a duct cyst or gland abscess, and marsupialization of a cyst; marsupialization should not be used to treat a gland abscess. Broad-spectrum antibiotic therapy is warranted only when cellulitis is present. Excisional biopsy is reserved for use in ruling out adenocarcinoma in menopausal or perimenopausal women with an irregular, nodular Bartholin's gland mass. (*Am Fam Physician* 2003;68:135-40. Copyright © 2003 American Academy of Family Physicians.)

Family physicians can expect to encounter Bartholin's duct cysts or gland abscesses in their female patients. These common problems often can be resolved with the use of simple office-based procedures such as Word catheter placement for duct cysts or gland abscesses, and marsupialization for duct cysts.

## Anatomy

Bartholin's glands (greater vestibular glands) are homologues of the Cowper's glands (bulbourethral glands) in males.<sup>1</sup> At puberty, these glands begin to function, providing moisture for the vestibule.

The Bartholin's glands develop from buds in the epithelium of the posterior area of the vestibule. The glands are located bilaterally at the base of the labia minora and drain through 2- to 2.5-cm-long ducts that empty into the vestibule at about the 4 o'clock and 8 o'clock positions<sup>2,3</sup> (Figure 1). The glands are

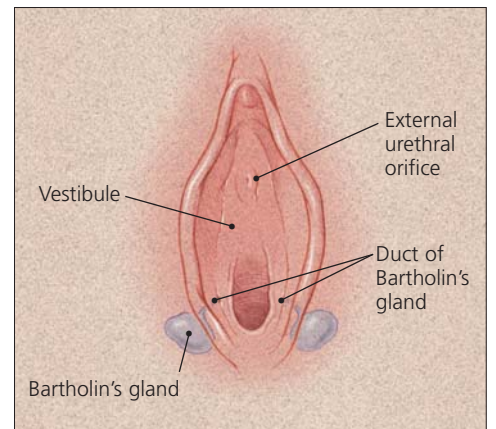


FIGURE 1. Anatomy of Bartholin's gland.

usually the size of a pea and rarely exceed 1 cm. They are not palpable except in the presence of disease or infection.

## Epidemiology

Bartholin's duct cysts, the most common cystic growths in the vulva,<sup>4,5</sup> occur in the labia majora.<sup>6</sup> Two percent of women develop a Bartholin's duct cyst or gland abscess at some time in life.<sup>6</sup> Abscesses are almost three times more common than cysts. One case-control study<sup>7</sup> found that white and black women were more likely to develop Bartholin's cysts or

*Bartholin's gland abscesses are almost three times more common than Bartholin's duct cysts.*

Obstruction of the distal Bartholin's duct may result in the retention of secretions and the formation of a cyst.

abscesses than Hispanic women, and that women of high parity were at lowest risk.

Gradual involution of the Bartholin's glands can occur by the time a woman reaches 30 years of age.<sup>8</sup> This may account for the more frequent occurrence of Bartholin's duct cysts and gland abscesses during the reproductive years, especially between 20 and 29 years of age.

Because a vulvar mass in a postmenopausal woman can be cancer, excisional biopsy may be required. Some investigators<sup>9</sup> have suggested that surgical excision is unnecessary because of the low risk of Bartholin's gland cancer (0.114 cancers per 100,000 woman-years). However, if the diagnosis of cancer is delayed, the prognosis can be poor.

### Pathology

Obstruction of the distal Bartholin's duct may result in the retention of secretions, with resultant dilation of the duct and formation of a cyst. The cyst may become infected, and an abscess may develop in the gland. A Bartholin's duct cyst does not necessarily have to be present before a gland abscess develops.<sup>10</sup>

TABLE 1  
Isolates from Bartholin's Gland Abscesses

Aerobic organisms	Anaerobic organisms
<i>Neisseria gonorrhoeae</i>	<i>Bacteroides fragilis</i>
<i>Staphylococcus aureus</i>	<i>Clostridium perfringens</i>
<i>Streptococcus faecalis</i>	Peptostreptococcus species
<i>Escherichia coli</i>	
<i>Pseudomonas aeruginosa</i>	Fusobacterium species
<i>Chlamydia trachomatis</i>	

Information from references 4, 11, and 12.

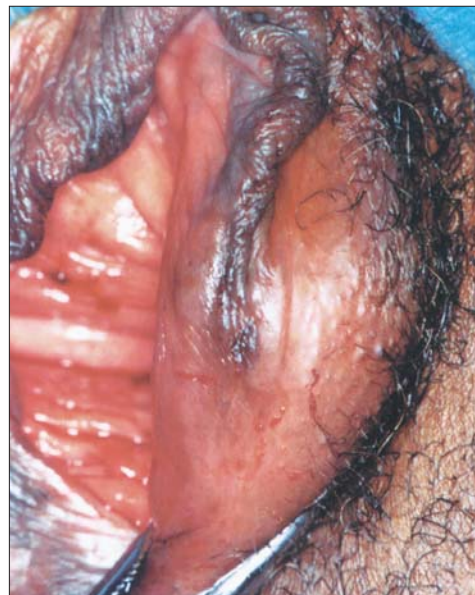

FIGURE 2. Bartholin's gland abscess.

Reprinted with permission from Wilkinson EJ, Stone IK. Atlas of vulvar disease. 5th ed. Baltimore: Williams & Wilkins, 1995:11-5.

Bartholin's gland abscesses are polymicrobial (Table 1).<sup>4,11,12</sup> Although *Neisseria gonorrhoeae* is the predominant aerobic isolate, anaerobes are the most common pathogens.<sup>10,11,13</sup> *Chlamydia trachomatis* also may be a causative organism.<sup>14</sup> However, Bartholin's duct cysts and gland abscesses are no longer considered to be exclusively the result of sexually transmitted infections.<sup>4</sup> Vulvovaginal surgery is an uncommon cause of these cysts and abscesses.<sup>15</sup>

### Presentation

If a Bartholin's duct cyst remains small and does not become inflamed, it may be asymptomatic. However, the cyst typically presents as a medially protruding mass in the posterior introitus in the region where the duct opens into the vestibule.<sup>10</sup> If the cyst becomes infected, an abscess may form in the gland (Figure 2).<sup>10</sup> Induration usually is present around the gland,<sup>10</sup> and walking, sitting, or sexual intercourse may result in vulvar pain.

TABLE 2  
Differential Diagnosis of Cystic and Solid Vulvar Lesions

<i>Lesion</i>	<i>Location</i>	<i>Characteristics</i>
<b>Cystic lesions</b>		
Bartholin's duct cyst	Vestibule	Usually unilateral; asymptomatic if remains small
Epidermal inclusion cyst	Labia majora (usually)	Benign, mobile, nontender; caused by trauma or obstruction of pilosebaceous ducts
Mucous cyst of the vestibule	Labia minora, vestibule, periclitoral area	Soft, less than 2 cm in diameter, smooth surface, superficial location; solitary or multiple; usually asymptomatic
Hidradenoma papilliferum	Between labia majora and labia minora	Benign, slow-growing, small nodule (2 mm to 3 cm); arises from apocrine sweat glands
Cyst of the canal of Nuck	Labia majora, mons pubis	Soft, compressible; peritoneum entrapped within round ligament; may mimic inguinal hernia
Skene's duct cyst	Adjacent to urethral meatus in vestibule	Benign, asymptomatic; if large, may cause urethral obstruction and urinary retention
<b>Solid lesions</b>		
Fibroma	Labia majora, perineal body, introitus	Firm, asymptomatic; may develop pedicle; may undergo myxomatous degeneration; potential for malignancy
Lipoma	Labia majora, clitoris	Benign, slow-growing; sessile or pedunculated
Leiomyoma	Labia majora	Rare; solitary, firm; arises from smooth muscle
Acrochordon	Labia majora	Benign, fleshy, variable size; usually pedunculated but may be sessile; polypoid in appearance
Neurofibroma	Multicentric	Small, fleshy; polypoid in appearance; multiple; associated with von Recklinghausen's disease
Angiokeratoma	Multicentric	Rare, benign; vascular; variable size and shape; single or multiple; associated with and aggravated by pregnancy; associated with Fabry's disease
Squamous cell carcinoma	Multicentric	Related to benign epithelial disease in older women and to human papillomavirus infection in young women

Bartholin's duct cysts and gland abscesses must be differentiated from other vulvar masses.<sup>1,6,8,10</sup> The most common cystic and solid vulvar lesions are listed in *Table 2*. Because the Bartholin's glands usually shrink during menopause, a vulvar growth in a postmenopausal woman should be evaluated for malignancy, especially if the mass is irregular, nodular, and persistently indurated.<sup>10</sup>

### Treatment

The treatment of a Bartholin's duct cyst depends on the patient's symptoms. An

asymptomatic cyst may require no treatment,<sup>2</sup> but symptomatic Bartholin's duct cysts and gland abscesses require drainage. Unless spontaneous rupture occurs, an abscess rarely resolves on its own.

Although incision and drainage is a rela-

*A vulvar growth in a postmenopausal woman should be evaluated for malignancy, especially if the mass is irregular, nodular, and persistently indurated.*

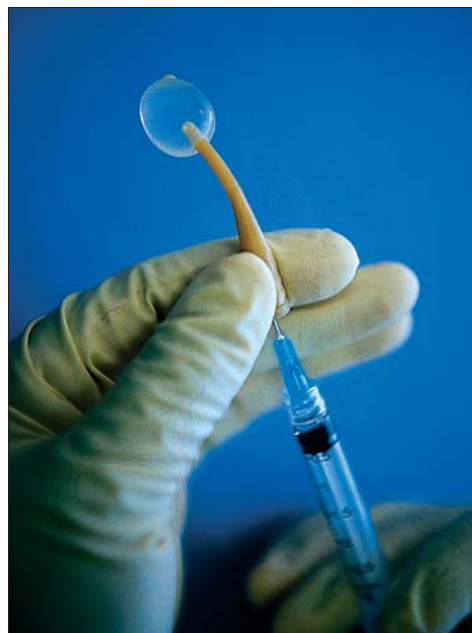**TABLE 3**  
**Supplies for Word Catheter Placement**

---

Sterile gloves
Iodine solution
Lidocaine (Xylocaine), 1% or 2% solution
30-gauge, 1-inch needle with 5-mL syringe for injecting lidocaine
Word catheter
Saline solution, 3 mL
25-gauge, 1-inch needle with 3-mL syringe for inflating balloon with saline solution
Small forceps for grasping cyst wall
No. 11 scalpel
Gauze pads, 4 × 4 inch
Hemostats to break up loculations

---

tively quick and easy procedure that provides almost immediate relief to the patient, this approach should be discouraged because there is a tendency for the cyst or abscess to recur.<sup>1,5,16</sup> One investigator<sup>17</sup> reported a 13 percent failure rate for the procedure. Furthermore, incision and drainage may make later Word catheter placement or marsupialization difficult.<sup>1,16</sup>



**FIGURE 3.** Inflated Word catheter.

Definitive drainage involves Word catheter placement for Bartholin's duct cysts and gland abscesses, and marsupialization for duct cysts.

#### **WORD CATHETER**

A Word catheter is commonly used to treat Bartholin's duct cysts and gland abscesses.<sup>12</sup> The stem of this rubber catheter is 1 inch long and the diameter of a no. 10 French Foley catheter. The small, inflatable balloon tip of the Word catheter can hold about 3 mL of saline (*Figure 3*).

After sterile preparation and the administration of a local anesthetic, the wall of the cyst or abscess is grasped with a small forceps, and a no. 11 blade is used to make a 5-mm (stab) incision into the cyst or abscess<sup>2,16</sup> (*Table 3*). It is important to grasp the cyst wall before the incision is made; otherwise the cyst can collapse, and a false tract may be created.<sup>16</sup> The incision should be within the introitus external to the hymenal ring in the area of the duct orifice.<sup>10,16</sup> If the incision is too large, the Word catheter will fall out.

---

#### **The Authors**

FOLASHADE OMOLE, M.D., is assistant professor in the Department of Family Medicine at Morehouse School of Medicine, Atlanta, where she also serves as associate residency director and predoctoral program director. A graduate of Obafemi Awolowo University in Nigeria, Dr. Omole completed a family medicine residency at Morehouse School of Medicine.

BARBARA J. SIMMONS, M.D., is assistant professor in the Department of Family Medicine at Morehouse School of Medicine. Dr. Simmons received her medical degree from the State University of New York Health Science Center at Brooklyn College of Medicine and completed a residency in obstetrics and gynecology at New York University Medical Center, New York, N.Y.

YOLANDA HACKER, M.D., is assistant professor in the Department of Family Medicine at Morehouse School of Medicine. Dr. Hacker graduated from the University of the West Indies, Jamaica, and completed a family medicine residency at Morehouse School of Medicine.

*Address correspondence to Folashade Omole, M.D., Department of Family Medicine, Morehouse School of Medicine, 505 Fairburn Rd., SW, Atlanta, GA 30331 (e-mail: omoyinf@msm.edu). Reprints are not available from the authors.*

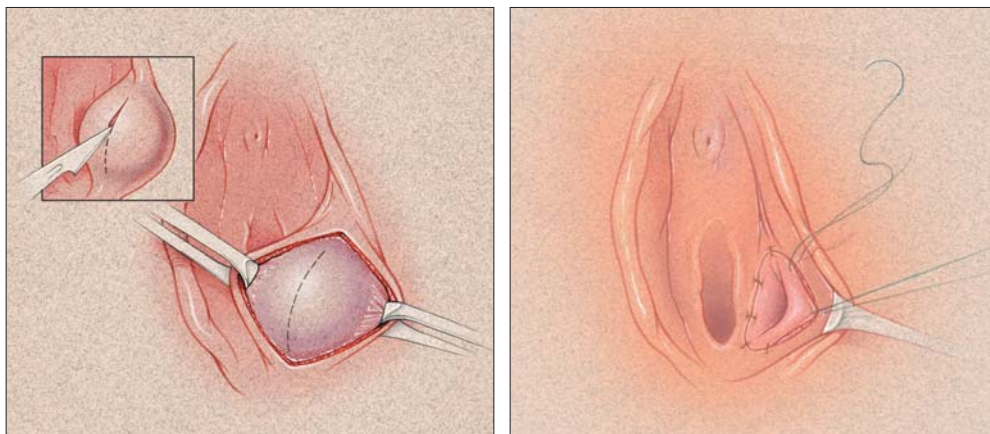


FIGURE 4. Marsupialization of Bartholin's duct cyst. (Left) A vertical incision is made over the center of the cyst to dissect it free of mucosa. (Right) The cyst wall is everted and approximated to the edge of the vestibular mucosa with interrupted sutures.

After the incision is made, the Word catheter is inserted, and the balloon tip is inflated with 2 to 3 mL of saline solution injected through the hub of the catheter. The inflated balloon allows the catheter to remain within the cavity of the cyst or abscess (Figure 3). The free end of the catheter can be placed in the vagina.<sup>16</sup> To allow epithelialization of the surgically created tract, the Word catheter is left in place for four to six weeks,<sup>1,10,16</sup> although epithelialization may occur as soon as three to four weeks.<sup>18</sup>

Sitz baths taken two to three times daily

TABLE 4  
Supplies for Marsupialization

Sterile gloves
Iodine solution
Lidocaine (Xylocaine), 1% or 2% solution
25-gauge, 1-inch needle with 5-mL syringe for injecting lidocaine
No. 11 scalpel
Two small hemostats for grasping cyst wall
Gauze pads, 4 × 4 inch
Hemostats to break up loculations
Small needle threaded with 2-0 absorbable suture
Needle holder
Scissors

may aid patient comfort and healing during the immediate postoperative period. Coitus may be resumed after catheter insertion.

Unless there is evidence of cellulitis, antibiotic therapy is unnecessary. If cellulitis is present, cultures may be obtained, but the results rarely change management. Empiric broad-spectrum antibiotic therapy is started before culture results are available.<sup>13</sup>

If a Bartholin's cyst or abscess is too deep, Word catheter placement is impractical, and other options must be considered.<sup>10</sup>

#### MARSUPIALIZATION

An alternative to Word catheter placement is marsupialization of a Bartholin's cyst (Figure 4). This procedure should not be used when an abscess is present.<sup>10</sup> Marsupialization can be performed in the office or, if the cyst is deeply seated, in an outpatient surgical suite.

After sterile preparation and the administration of a local anesthetic, the cyst wall is grasped with two small hemostats<sup>2,16</sup> (Table 4).

*Marsupialization should not be used to manage an abscessed Bartholin's gland.*



A vertical incision is made in the vestibule over the center of the cyst and outside the hymenal ring.<sup>18</sup> The incision should be about 1.5 to 3 cm long, depending on the size of the cyst.

After the cyst is vertically excised, the cavity drains spontaneously. The cavity also may be irrigated with saline solution and, if necessary, loculations can be broken up with a hemostat. The cyst wall is then everted and approximated to the edge of the vestibular mucosa with interrupted 2-0 absorbable suture.<sup>18</sup> Daily sitz baths should begin on the first postoperative day.

Approximately 5 to 15 percent of Bartholin's duct cysts recur after marsupialization.<sup>18</sup> Complications associated with the procedure include dyspareunia, hematoma, and infection.<sup>1</sup>

### EXCISION

Although Bartholin's gland abscesses may rupture and drain spontaneously, recurrence is likely, and surgical excision may be necessary. Excision is not an office-based procedure.

Cultures for *N. gonorrhoeae* and *C. trachomatis* may be obtained. However, Bartholin's gland abscesses tend to be polymicrobial, and empiric broad-spectrum antibiotic therapy should be used.

Excision of the Bartholin's gland should be considered in patients who do not respond to conservative attempts to create a drainage tract, but the procedure should be performed when there is no active infection.<sup>1,4</sup> If multiple attempts have been made to drain a cyst or an abscess, adhesions may be present, making excision difficult and resulting in postoperative scarring and chronic pain in the area.<sup>2,10</sup>

Some investigators<sup>2,10</sup> recommend excision of the Bartholin's gland to exclude adenocarcinoma when cysts or abscesses occur in patients more than 40 years of age. Even though adenocarcinoma of the Bartholin's gland is rare, gynecologic oncology referral should be considered for older patients with Bartholin's duct cysts or gland abscesses.

*The authors indicate that they do not have any conflicts of interest. Sources of funding: none reported.*

*The authors thank Barbara S. Apgar, M.D., M.S., associate editor of AFP, for editorial assistance.*

### REFERENCES

1. Stenchever MA. Comprehensive gynecology. 4th ed. St. Louis: Mosby, 2001:482-6,645-6.
2. Hill DA, Lense JJ. Office management of Bartholin gland cysts and abscesses. *Am Fam Physician* 1998; 57:1611-6,1619-20.
3. Govan AD, Hodge C, Callander R. Gynaecology illustrated. 3d ed. New York: Churchill Livingstone, 1985:19,195-6.
4. Azzan BB. Bartholin's cyst and abscess. A review of treatment of 53 cases. *Br J Clin Pract* 1978;32(4): 101-2.
5. Kovar WR, Scott JC Jr. A practical, inexpensive office management of Bartholin's cyst and abscess. *Nebr Med J* 1983;68:254-5.
6. Kaufman RH. Benign diseases of the vulva and vagina. 4th ed. St. Louis: Mosby, 1994:168-248.
7. Aghajanian A, Bernstein L, Grimes DA. Bartholin's duct abscess and cyst: a case-control study. *South Med J* 1994;87:26-9.
8. Stillman FH, Muto MG. The vulva. In: Ryan KJ, Berkowitz RS, Barbieri RL, eds. *Kistner's Gynecology: principles and practice*. 6th ed. St. Louis: Mosby, 1995:66-8.
9. Visco AG, Del Priore G. Postmenopausal Bartholin gland enlargement: a hospital-based cancer risk assessment. *Obstet Gynecol* 1996;87:286-90.
10. Wilkinson EJ, Stone IK. Atlas of vulvar disease. 5th ed. Baltimore: Williams & Wilkins, 1995:11-5.
11. Cheetham DR. Bartholin's cyst: marsupialization or aspiration? *Am J Obstet Gynecol* 1985;152:569-70.
12. Word B. Office treatment of cyst and abscess of Bartholin's gland duct. *South Med J* 1968;61:514-8.
13. Brook I. Aerobic and anaerobic microbiology of Bartholin's abscess. *Surg Gynecol Obstet* 1989; 169:32-4.
14. Saul HM, Grossman MB. The role of *Chlamydia trachomatis* in Bartholin's gland abscess. *Am J Obstet Gynecol* 1988;158(3 pt 1):76-7.
15. Peters WA 3d. Bartholinitis after vulvovaginal surgery. *Am J Obstet Gynecol* 1998;178:1143-4.
16. Apgar BS. Bartholin's cyst/abscess: Word catheter insertion. In: Pfenninger JL, Fowler GC, eds. *Procedures for primary care physicians*. St. Louis: Mosby, 1994:596-600.
17. Mathews D. Marsupialization in the treatment of Bartholin's cysts and abscesses. *J Obstet Gynaecol Br Commonw* 1966;73:1010-2.
18. Horowitz IR, Buscema J, Woodruff JD. Surgical conditions of the vulva. In: Rock JA, Thompson JD, eds. *Te Linde's Operative gynecology*. 8th ed. Philadelphia: Lipincott-Raven, 1997:890-3.